CHANGES IN THE LIVERS OF MICE FED POLYOXYETHYLENE SORBITAN DERIVATIVES

JIM N. TONE
Illinois State University, Normal, Illinois

ABSTRACT.—A histochemical and histological study was made of the livers of male and female C57BL/6 mice fed a diet containing 5 or 10% polyoxyethylene sorbitan monolaurate or polyoxyethylene sorbitan monostearate for periods of 10, 18, 29, 34, 54, and 104 weeks. Hepatic focal necrosis and hemosiderosis were the apparent effects of the experimental diets.

A growing number of synthetic surface active agents are currently finding applications in the food industries. Among these, polyoxyethylene sorbitan monolaurate (PSML) and polyoxyethylene sorbitan monostearate (PSMS) have been used. PSML and PSMS are classified as food additives by the U.S. Food and Drug Administration, and have proved to be particularly useful in food processing as emulsifiers.

Several investigations dealing with the hepatic histopathology of these chemicals in various laboratory animals have shown no deleterious effects (Brush et al., 1957; Harris et al., 1951; Chow et al., 1953; Oser and Oser, 1957a). This is compatible with studies relating to the liver when human subjects ingested these and related esters (Kruesi and Van Itallie, 1956; Waldstein et al., 1954). However, in one study the prolonged feeding of a very high concentration of PSMS resulted in possible fatty changes in the liver of some rats (Fitzhugh et al., 1959). In another study, Eagle and Poling (1956) observed diarrhea and liver changes with a highly synthetic diet low in bulk containing PSML.

The present investigation was undertaken to determine the histopathological effects of high dietary levels of PSML or PSMS on the livers of C57BL/6 mice.

METHODS

A local stock of C57BL/6 mice was established and maintained by brother-sister matings. In all cases, mice were weaned at 3 weeks, and then fed Purina Mouse Breeder Chow (fiber content of 2%) in pellet form until 8 weeks old.

Six experiments based upon period of time on a diet were set up: 10, 18, 29, 34, 54, and 104 weeks. Ten control animals (5 males and 5 females) were killed at 8 weeks of age (age of mice at start of each experiment). Except for the 104 week category, mice were randomly divided into groups of 10 each (5 females and 5 males), and were fed either a basal diet of Purina Mouse Breeder Chow in mash form or experimental diets of Purina Mouse Breeder Chow in mash form containing, by weight, 5% PSML or PSMS, or 10% PSML or PSMS. In the 104 week group only female mice were utilized because male mice of the correct age were not available at the time this experiment was initiated.

Mice in each experiment, randomly grouped into five according to sex, were placed in plastic cages provided with perforated steel lid, and wood shavings

for bedding. Animal room temperature was maintained at approximately 25°C. Weekly, each group of 5 mice was placed in a clean cage provided with fresh bedding, clean food receptacle and watering apparatus. Food and water were supplied *ad libitum*.

Routinely, food was removed from the animals 10 hours before killing which took place between 8:00 A.M. and 9:00 A.M. in order to minimize any diurnal variation effect. Mice were killed by a sharp blow on the back of the head. The abdominal cavity was immediately opened, and samples of the anterior region of the median liver lobe were removed rapidly and placed in fresh Carnoy's fixative and 10% neutral formalin.

After fixation the tissue was dehydrated in ethanol, cleared in xylene, and embedded in a mixture of 90% paraffin, 10% bayberry wax at 58°C.

Liver fixed by Carnoy's solution was sectioned at 4 and 7 μ, stained by the periodic acid-Schiff (PAS) technique and counterstained with Mayer's hemalum (Lillie, 1954). Adjacent series of sections of each liver were treated with malt diastase for 45 minutes at 35-45°C. and then stained in the same manner.

Liver fixed by 10% neutral formalin was sectioned at 7 μ, treated according to the ferrocyanide reaction of Perl (Lillie, 1954) and counterstained with safranin 0.

Results and Discussion

Diarrhea was apparent throughout life in mice fed PSML or PSMS, moderate at 10% and slight at 5%. No evidence of tumors or other abnormal growths was found in any animal either during the course of the experiments or at autopsy. No significant abnormalities in behavior or physical appearance were observed in any of the groups.

Wide-spread pericentral infiltration of the hepatic cells by masses of lymphocytes and connective tissue elements was observed (Fig. 1, A and B). In these regions there was an actual destruction of the hepatic cells and their replacement by masses of connective cells on a framework of delicate fibers. The incidence of pericentral infiltration was similar in control and experimental animals. However, the degree of infiltration was greater in the experimental diets.

Among the conditions observed in the hepatic cells was a change which will be referred to as cytoplasmic vacuolation (Fig. 1, C). This was interpreted as fatty change. In all cases the cytoplasm in hepatic cells with vacuolation showed PAS positive material, and vacuolated cells were usually located centrally in the lobules.

At 54 weeks, most of the mice in all experimental diet groups possessed many hepatic cells with very pronounced cytoplasmic vacuolation in all regions, in addition to the central area of the lobules.

Because the cytoplasm of a hepatic cell in normal mice may present a variable appearance that reflects the functional state of the cells, the relationship between PSML or PSMS effects and presence of cytoplasmic vacuolation should be evaluated accordingly. A few experimental animals developed hepatic cell vacuolation a few weeks earlier than the controls. While the incidence of such alterations was similar in control and experimental animals, the extent of vacuolation was greater in the experimental diets.

Significant microscopic observations from mice in all experiments are summarized in tabular form (Table 1).

Necrotic lesions of relatively small areas within hepatic tissues were observed. Necrotic cells were pyknotic and had no detectable glycogen

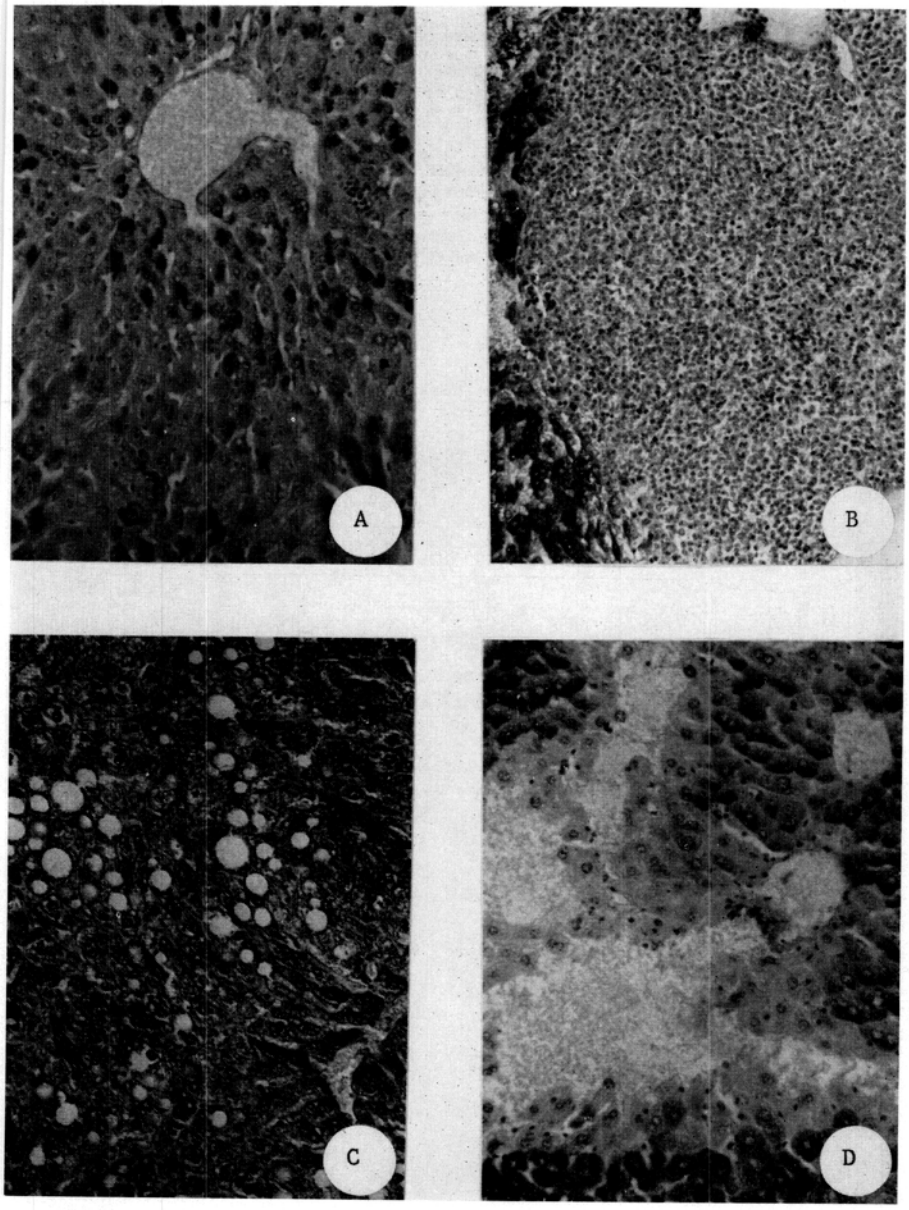

FIGURE 1.—Sections of central vein regions in livers of male mice. Feeding time: 34 weeks. PAS and hemalum. X160. A., control diet; B., PSMS-10% diet, pericentral infiltration; C., PSMS-10% diet, cytoplasmic vacuolation of hepatic cells; and D., PSMS-10% diet, intralobular necrotic lesion.

TABLE 1.—Incidence of Hepatic Histopathology in Mice Fed Polyoxyethylene Sorbitan Monolaurate (PSML) or Polyoxyethylene Sorbitan Monostearate (PSMS).

Histological Finding	Feeding Time (Weeks)[1]	Diets									
		Control		+ PSML, %				+ PSMS, %			
				5		10		5		10	
		M	F	M	F	M	F	M	F	M	F
Necrosis	10	0(5)[2]	0(5)	0(5)	0(5)	0(5)	0(5)	3(5)	4(5)	2(4)	2(4)
	18	0(5)	0(5)	0(4)	0(5)	0(4)	0(5)	2(4)	3(5)	3(5)	4(5)
	29	0(3)	0(5)	0(5)	0(5)	3(5)	3(5)	4(5)	3(5)	2(5)	5(5)
	34	0(5)	0(5)	3(5)	3(4)	4(5)	4(4)	1(5)	4(5)	4(5)	4(4)
	54	1(5)	2(3)	1(3)	5(5)	3(3)	4(5)	4(5)	4(4)	4(5)	4(4)
	104[3]	.....	2(2)	.....	5(5)	.....	4(4)	.....	1(1)	.....	4(4)
Hemosiderosis	10	0	0	0	1	0	2	3	4	2	2
	18	0	0	0	0	0	3	2	3	3	4
	29	0	0	0	2	3	4	4	3	2	5
	34	0	0	0	1	3	4	1	4	4	4
	54	0	0	0	3	0	4	4	4	4	4
	104	.....	1	.....	1	.....	4	.....	1	.....	4

[1] Age of animals in each feeding period equals feeding time plus 8 weeks; 5 male and 5 female control animals (8 weeks old) were negative for all histological findings listed.

[2] Number in parentheses represents number of surviving animals examined at the end of each period.

[3] Only female animals were used at this period.

in the cytoplasm (Fig. 1, D). Often the small areas of necrosis were infiltrated with leucocytes.

The total incidence of animals with focal necrosis of hepatic cells was the following for each diet: (1) control, 5/48 (10%); (2) PSML-5%, 17/51 (34%); (3) PSML-10%, 25/50 (50%); (4) PSMS-5%, 33/49 (67%); (5) PSMS-10%, 38/50 (76%). When the chi square test was applied on these findings, each one of the experimental groups compared to the controls was significantly different ($P<0.05$).

Focal necrosis of hepatic cells appears to be one of the more apparent changes associated with feeding of PSML or PSMS to this specific strain of mice and with this specific diet. This was especially true for animals fed PSMS. Not only was the frequency of hepatic necrosis greater among animals fed PSMS, but the occurrence of necrotic lesions was generally more frequent at shorter feeding periods. While the frequencies in PSML animals exhibiting necrosis of hepatic cells were indicative of an effect, the later appearance of these necrotic regions indicated that PSML was less effective than PSMS in inducing necrosis upon younger tissue.

PSMS and PSML are readily split in the gastrointestinal tract to absorable fatty acids and unabsorbed polyols, which produce diarrhea if present in high levels in rats (Oser and Oser, 1957b). Since in relation to body weight, the mouse eats about three times as much feed as the rat does, and since diarrhea is enhanced with a diet low in fiber, diarrhea in these experimental mice is not unexpected. Although it may not be definitely established, the role of diarrhea was important in the induction of certain hepatic lesions in this strain of susceptible mice.

The total incidence of animals with hemosiderosis of the liver was the following for each diet: (1) control, 1/48 (2%); (2) PSML-5%, 8/51 (16%); (3) PSML-10%, 27/50 (54%); (4) PSMS-5%, 33/49 (67%); (5) PSMS-10%, 38/50 (76%). A chi square test between each experimental group and controls indicated a significant difference ($P<0.001$) for PSML-10%, PSMS-5%, and PSMS-10%.

In all cases the bile ducts, branches of the hepatic artery, and interlobular veins appeared histologically normal. Although there was some increase in connective tissue elements in livers showing infiltration, in no case did the amount of infiltration approach that characteristic of a cirrhosis.

Literature Cited

Brush, M. K., J. R. McCoy, H. L. Rosenthal, L. A. Stauber, and J. B. Allison. 1957. The addition of non-ionic surface-active agents of the polyoxyethylene type to the diet of the hamster, the mouse, and the dog. J. Nutr. 62:601-620.

Chow, B. F., J. M. Burnett, C. T. Ling, and L. Barrows. 1953. Effects of basal diets on the response to certain dietary non-ionic surface-active agents. J. Nutr. 49:563-578.

Eagle, E., and C. E. Poling. 1956. The oral toxicity of polyoxyethylene derivatives in rats and hamsters. Food Res. 21:348-361.

Fitzhugh, O. M., A. R. Bourke, A. A. Nelson, and J. P. Frawley. 1959. Chronic oral toxicities of four stearic acid emulsifiers. Toxicol Appl. Pharmacol. 1:315-331.

Harris, R. S., H. Sherman, and W. W. Jetter. 1951. Nutritional and pathological effects of sorbitan monolaurate, polyoxyethylene sorbitan monolaurate,

polyoxyethylene monolaurate, and polyoxyethylene monostearate when fed to rats. Arch. Biochem. Biophys. 34:249-258.

KRUESI, O. R., and T. B. VAN ITALLIE. 1956. Effect of polyoxyethylene-8-monostearate (MYRJ 45) on liver function in patients convalescing from hepatic disorders. Food Res. 21:565-568.

LILLIE, R. D. 1954. Histopathologic Technic and Practical Histochemistry. Blakiston Company, Inc., New York. 123-124, 243-244.

OSER, B. L., and M. OSER. 1957a. Nutritional studies on rats on diets containing high levels of partial ester emulsifiers. IV. Mortality and post-mortem pathology; general conclusions. J. Nutr. 61:235-252.

———. 1957b. Nutritional studies on rats on diets containing high levels of partial ester emulsifiers. III. Clinical and metabolic observations. J. Nutr. 61:149-166.

WALDSTEIN, S. S., H. M. SCHOOLMAN, and H. POPPER. 1954. The effect of feeding large amounts of emulsified polyoxyethylene (20) sorbitan monostearate (TWEEN 60) and sorbitan monostearate (SPAN 60) to humans. Am. J. Dig. Diseases 21:181-185.

Manuscript received January 3, 1966.