DEVELOPMENT OF LATERAL CERVICAL FAT ORGANS IN THE CHICK WITH EMPHASIS ON RELATIONSHIPS TO THE ADJACENT MUSCULUS COMPLEXUS

FRANK RAY VOORHEES and RAY L. WATTERSON
Department of Biology
Knox College, Galesburg, Illinois and
Department of Zoology
University of Illinois, Urbana

ABSTRACT.—Structures immediately lateral to the Musculus complexus (hatching muscle) of chick embryos and early posthatching stages have been studied histologically and quantitatively. They proved to be fat organs rather than lymph glands as previously designated by some investigators. Possible reasons for quite parallel changes in mean fixed wet weights of the M. complexus and adjacent fat organs and diameters of vacuoles of the largest univacuolar fat cells are discussed.

In 1954 Liebelt and Eastlick described macroscopically the location, time of appearance and relative size and shape of 16 subcutaneous fat organs (fat bodies) in chick embryos. One of the largest and most distinct has an elongated triangular shape and is located in the dorsolateral cervical region (the lateral cervical fat organ). Clara (1929) had previously examined the histogenesis of some subcutaneous fat depots in a variety of birds and had recorded some observations on developing fat depots in the neck region of chick embryos, presumably on developing lateral cervical fat organs.

Other investigators interested in the peculiar developmental history of the avian hatching muscle (Musculus complexus) and its possible role in pipping and hatching had seen these prominent structures bordering the M. complexus of chick embryos (Fisher, 1958; Brandstetter, 1960; Smail, 1964, 1965; Brooks and Ungar, 1967) and had designated them as lymph glands; see illustrations in Fisher and Smail. Developmental changes in their size were reported to parallel closely changes in mass or size of the M. complexus of the chick (Fisher, 1958) and certain other birds (H. Fisher, 1962, 1966; J. Fisher, 1962), although they were absent in developing North American grebes (Fisher, 1961). Changes in size were deduced either from gross observations or from measurements of lengths and widths and sometimes from crude estimations of areas based on these measurements.

It is the purpose of this investigation on chick embryos and early posthatching stages to (1) describe the histogenesis of the structures bordering the M. complexus and to demonstrate that, at least in chicks, they are fat organs and not lymph glands and (2) ascertain to what extent weight changes and changes in diameters of individual fat cells of the lateral cervical fat organs parallel weight changes in the M. complexus.

Materials and Methods

Fertile White Leghorn eggs were used exclusively; they were incubated at 37.5°C in a forced draft incubator. All specimens were killed by decapitation at the base of the neck. Only the head and neck were preserved in Bouin's fixative and subsequently decolorized in 70% ethanol and lithium carbonate. Specimens were preserved daily between 7 days of incubation and 6 days posthatching for histological study. Selected regions (the entire neck and part of the head of younger specimens, only fat organs plus a portion of the adjacent M. complexus in chicks incubated more than 16 days) were sectioned serially in paraffin at 20 μ, both transversely and sagittally, and stained with Heidenhain's iron hematoxylin and eosin Y.

To provide material for weight determinations specimens were preserved at 13, 15 and 16 days of incubation and daily from 18 days of incubation through 3 days posthatching (Table 1). Hatchlings were given free access to water, but most were not fed. Six chicks were fed chick starter for 2 days, 18 for 3 days. Preserved fat organs and paired M. complexus muscles were then carefully isolated. The jugular vein and vagus nerve were carefully removed from these isolated organs and the latter were then blotted for 5 seconds and weighed. Mean fixed wet weights and standard errors of the means were calculated. The t-test was used to determine whether weight changes between different days were statistically significant. Most differences were highly significant ($P \leqq 0.01$), but some were only significant ($P \leqq 0.05 > 0.01$).

Observations

Gross relationships. Although the origins, and insertions of the M. complexus have been repeatedly described (Beddard, 1898; Kaupp, 1918; Fisher, 1958; George and Berger, 1966; Brooks and Ungar, 1967; Bock and Hikida, 1968), the gross relationships of the muscle to the head of the chick have been illustrated only by the diagrams of Fisher (1958) and Bock and Hikida (1968, 1969) and by the photographs of Brandstetter (1960) and Smail (1964, 1965). The location and appearance of the M. complexus in a chick preserved shortly after hatching are evident in Figure 1. The muscle forms a prominent bulge at the back of the head and upper part of the neck.

The complete extent of the right lateral cervical fat organ is evident in Figure 1. It is roughly triangular in shape with the base of the triangle directed anteriorly. Its general shape and size relative to the rest of the head and neck correspond exactly with the schematic representations of the lateral cervical fat organs published by Liebelt and Eastlick (1954) to represent relationships in 12-, 14- and 16-day chick embryos.

The gross relationship of the lateral cervical fat organ to the M. complexus is also clearly illustrated in transverse section in Figure 2. The former not only lies dorsolateral to the M. complexus, but obviously extends far ventrad towards the esophagus. The lateral cervical fat organ is obviously only loosely attached to adjacent structures. Therefore it can be removed cleanly for weighing, but only in preserved

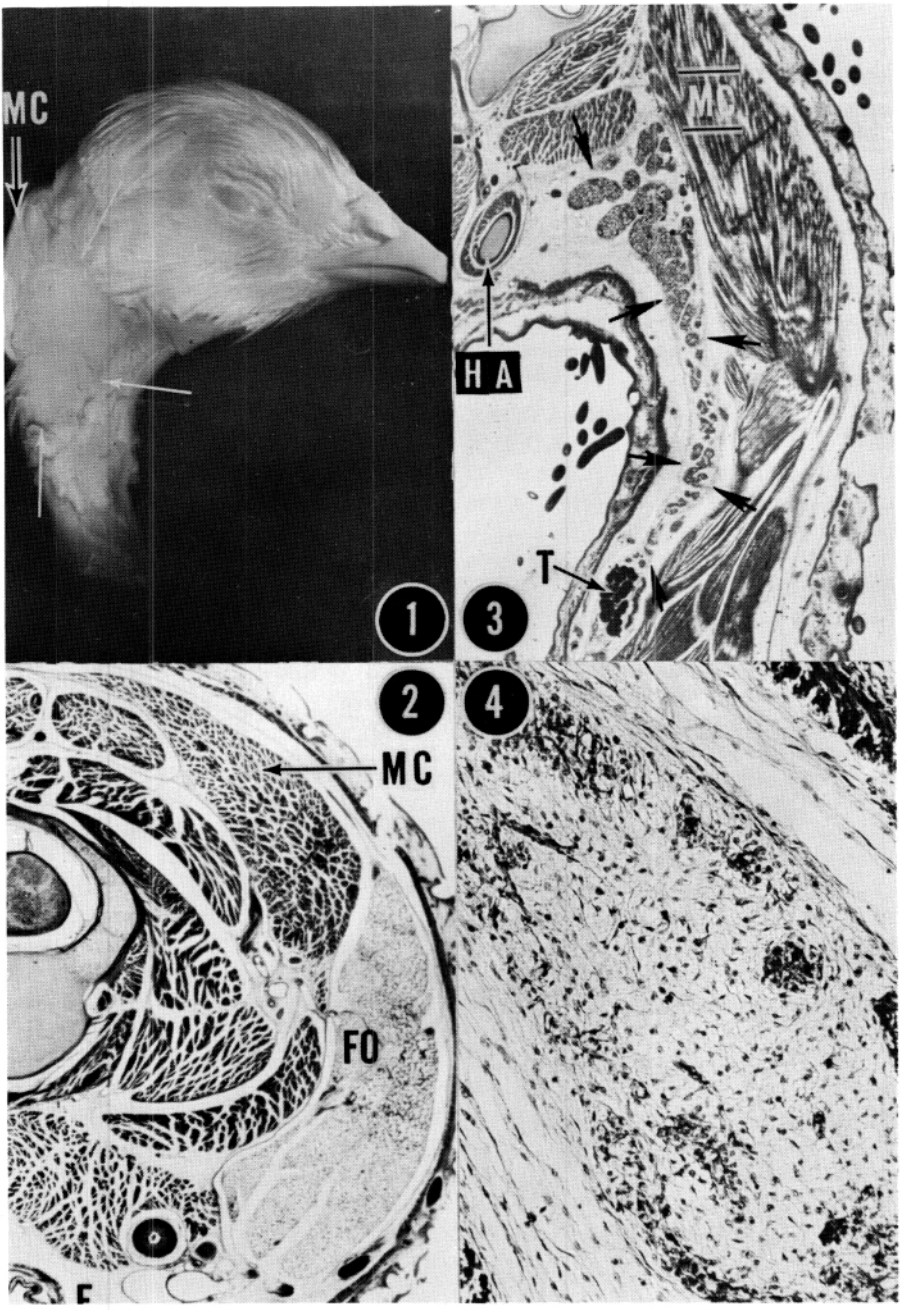

PLATE 1
(See p. 427)

specimens. In specimens used for this investigation the esophagus was frequently displaced to the right. Under these circumstances the lateral cervical fat organ was much smaller on the right side than on the left.

The lateral cervical fat organ is also roughly triangular in shape in parasagittal sections (Fig. 3). The broad anterior end lies between the M. complexus dorsally and the hyoid arch ventrally; the narrow posterior end lies in contact with the anterior lobe of the thymus. The latter is the only lymphoid organ in the neck; it obviously lies far posterior to the M. complexus. According to Hamilton (1952) the chick does not possess definite lymph nodes such as are found in mammals, although Clara (1929) refers to "Halslymphknotens."

Histogenesis. Rudiments of lateral cervical fat organs cannot be identified in specimens incubated 7½-9 days. Ten-day specimens were not examined histologically in the present investigation. By 11 days (stage 37) rudiments of these particular fat organs can be identified. A transverse section showing most of the dorsoventral extent of such a rudiment is illustrated by Figure 4. It is tear-shaped, very narrow and somewhat pointed dorsally and broad and rounded ventrally. Its connective tissue component is considerably more dense and contains many more fibers (processes?) than the adjacent loose connective tissue. The darker masses within the boundaries of the rudiment consist of capillaries or capillary networks plus adjacent adventitial cells (prospective fat cells) which form a single or double layer outside the endothelium of capillaries. Nuclei of these perivascular mesenchymal cells are distinctly different from those of fibrocytes. They are spherical or nearly so, in contrast to the oval shape of fibrocyte nuclei. Nuclei of young prospective fat cells are also generally smaller and stain more intensely than those of fibrocytes.

The larger clusters of prospective fat cells are usually found around capillary networks. Such clusters are highly variable in size and shape. Sometimes a capillary interconnects two otherwise independent clusters. Some of the prospective fat cells are undergoing mitosis. Erythrocytes occur both within capillaries and outside the latter. At 11 days fat droplets are not present; at least they cannot be detected at a magnification of 400X.

By 12 days (stage 38) boundaries of lateral cervical fat organs are very distinct in parasagittal sections (Fig. 3). Clusters of young fat cells in close relation to capillaries form more or less independent lobules separated by fibrocytes. A portion of the lateral cervical fat organ at stage 38 is illustrated at higher magnification in Figure 5. The darkest portions of this photomicrograph consist of capillaries containing erythrocytes with darkly stained nuclei. The very light portions are vacuoles from which fat was extracted by histological procedures. The largest vacuoles may be the single vacuoles of univacuolar fat cells. These are approximately 15.5 μ in diameter. Most of the vacuoles are smaller and grade down to those barely visible at a magnification of 400X. These smaller

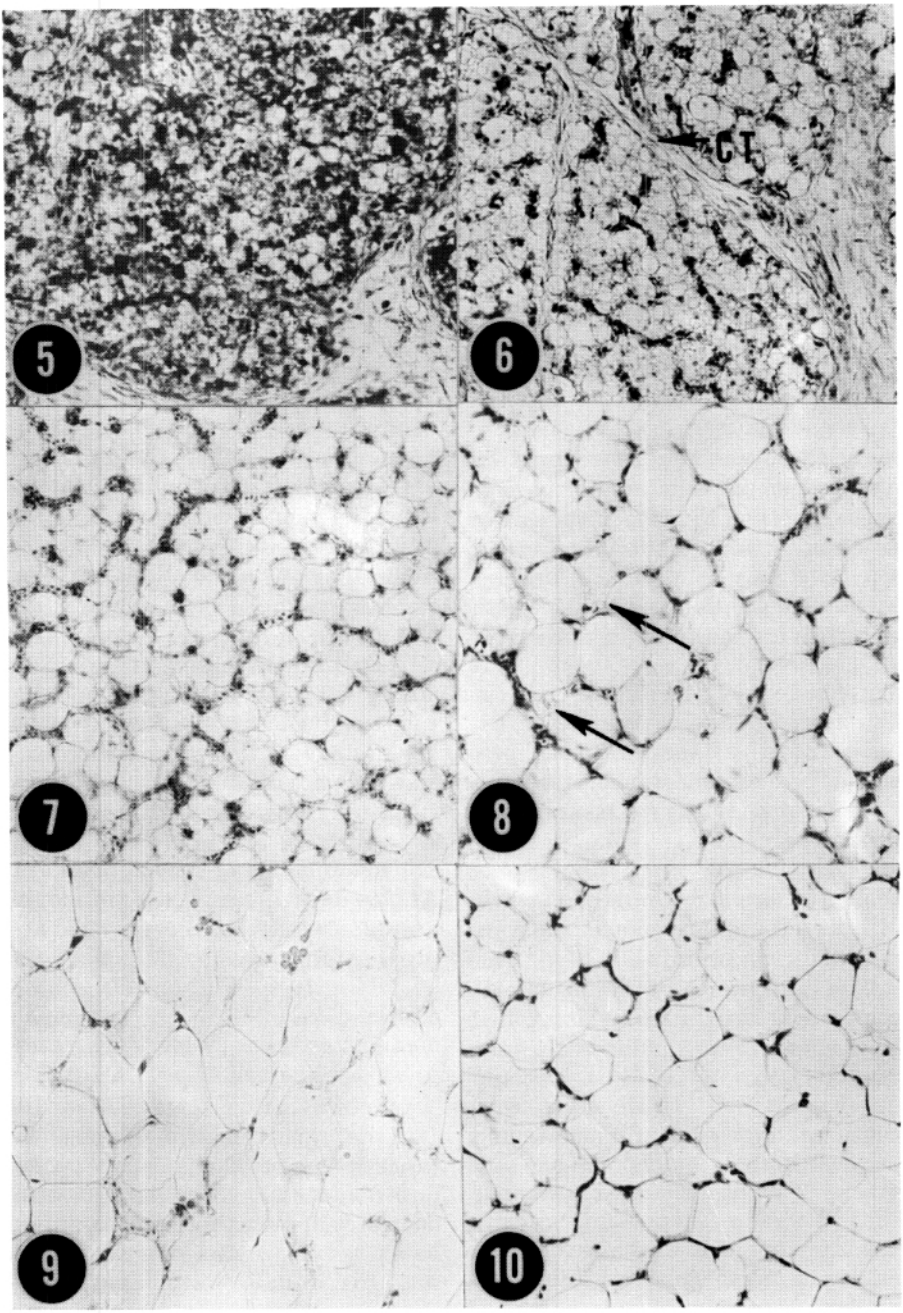

PLATE II
(See p. 427)

vacuoles are presumably located in plurivacuolar fat cells, although the outlines of individual cells cannot be identified with certainty in the thick sections used in the present investigation. Regardless of their size vacuoles are approximately circular in outline. Mitotic figures are present in some of the cells containing small vacuoles. Therefore the presence of fat droplets is compatible with mitotic division. Very few fibrocytes are present within fat lobules, but they separate lobules from one another.

By 13 days (stage 39) increasing numbers of fat cells are of the univacuolar type (Fig. 6). Lobules are now closely adjacent to one another, separated only by thin septa formed by fibrocytes. Capillaries filled with erythrocytes containing darkly stained nuclei are very evident, but are more widely separated than at 12 days (compare with Fig. 5). Diameters of the largest vacuoles, presumably the single vacuoles of univacuolar fat cells, now measure approximately 25 μ. Many plurivacuolar fat cells are still present; their vacuoles vary markedly in size. Mitotic figures are much less common than at 12 days.

The appearance of 14-day lateral cervical fat organs is not illustrated since Clara (1929) published a very accurate drawing of this stage in his Figure 10. Univacuolar cells continue to increase in diameter and become closely applied to one another. Plurivacuolar cells assume very irregular shapes and occupy whatever space is available between enlarging univacuolar cells and capillaries.

By 15 days (stage 41) the cross-sectional area of the lateral cervical fat organ is very large compared with other structures in the neck region (Fig. 2). Higher magnification (Fig. 7) shows that most fat cells are now of the univacuolar type. Diameters of the largest vacuoles usually have increased to approximately 34.5 μ, but a few have increased to 44 μ. Capillaries become increasingly compressed by enlarging fat cells. Some plurivacuolar cells are still present; their contained vacuoles are still of variable size. However, the number of plurivacuolar cells has clearly decreased as increasing numbers of them transform into univacuolar cells. Mitotic figures are very rare and are found only in the smallest fat cells.

With continued incubation diameters of the largest univacuolar fat cells continue to increase to approximately 72 μ at 16 days (stage 42, Fig. 8) and to 81 to 91.5 μ at 19-20 days (stage 45, Fig. 9). Plurivacuolar cells are still evident at 16 days (arrows, Fig. 8) but they, as well as capillaries, are progressively less evident as hatching time approaches. At 16 days outlines of individual univacuolar fat cells are still approximately circular (Fig. 8), but by 19-20 days (Fig. 9) the shapes of these cells become very much modified as the very large cells compress one another.

In posthatching stages (Figs. 10-12) the appearance of univacuolar fat cells does not change appreciably, but diameters of the largest ones decrease appreciably shortly after hatching: 78 μ at 1 day posthatching (Fig. 10); 59.5 μ at 3 days posthatching (Fig. 11); 47 μ at 6 days posthatching (Fig. 12). During

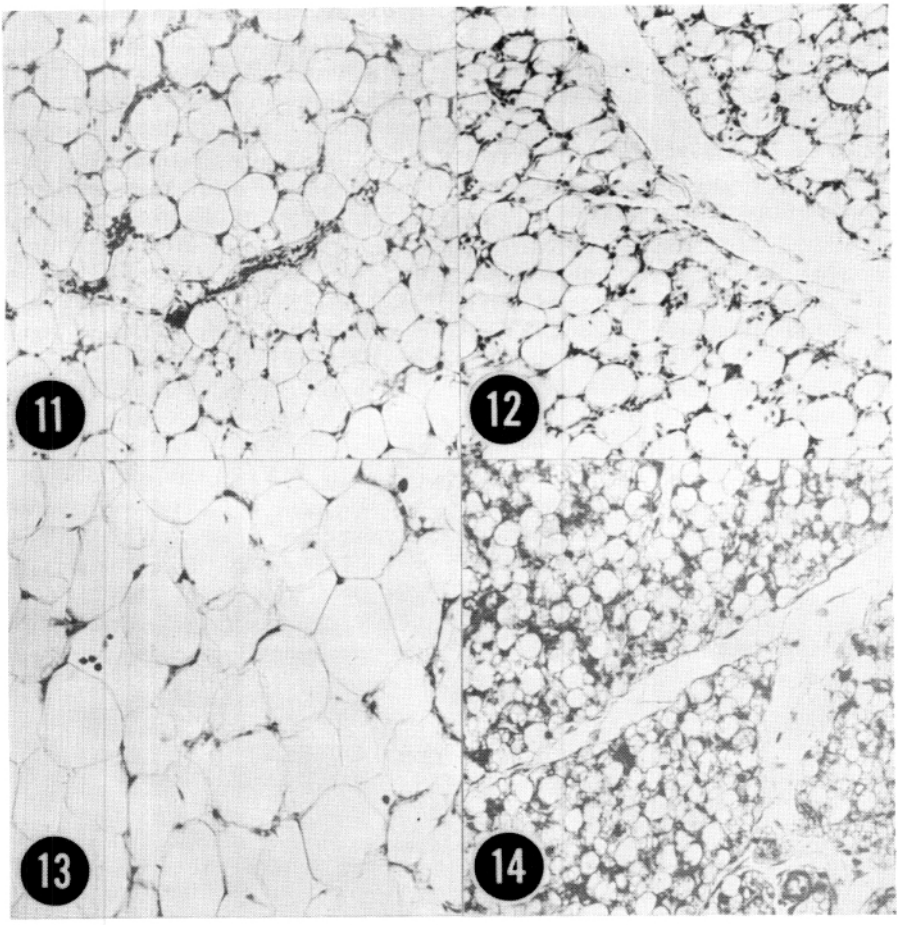

PLATE III
(See p. 427)

posthatching stages lobules within lateral cervical fat organs become increasingly separated from one another (Fig. 12) and capillaries become increasingly evident.

It is not known whether all fat organs of chickens undergo the same developmental sequence involving first an increase and then a decrease in the size of individual fat cells. But if they do, corresponding changes apparently do not occur at the same time in all fat organs. At 21 days of incubation the histology of the lateral *abdominal* fat organ (Fig. 13) is essentially the same as that of the lateral cervical fat organ of 19- to 20-day chick embryos (Fig. 9). By contrast, the histology of the lateral *thoracic* fat organ at 21 days (Fig. 14) is entirely different. The latter has either failed to develop to the same extent as the other 2 fat organs or, more likely (see

below), has secondarily lost much of its fat content.

Quantitative changes. Mean fixed wet weights of paired M. complexus and paired lateral cervical fat organs are recorded in Table 1 and are plotted in Figure 15. For comparison the unpublished data of Watterson and Veneziano on mean fresh weights of the M. complexus are also plotted in Figure 15. At 2 and 3 days posthatching (23 and 24 days from onset of incubation) data were obtained and plotted for both fed and unfed chicks.

Mean fresh weights of the M. complexus increase rapidly to a peak at 20 days, the day of pipping, then decrease rapidly. Mean fixed wet weights behave somewhat differently. They increase slightly from 13 to 16 days (although the apparent increase between 15 and 16 days is not statistically significant), then increase rapidly to an apparent maximum at 21 days (although differences between 18- and 19-day and between 20- and 21-day values are not statistically significant) and then decrease progressively and rapidly. Values at 21 to 23 days are quite similar to fresh weight values, but fresh weight values are consistently larger than fixed weight values at earlier stages, especially at 19 and 20 days when the water content of the M. complexus is normally very high. Fixed weight values in posthatching stages are the same in fed and unfed chicks (Table 1).

Mean fixed wet weights of lateral cervical fat organs are slightly larger at 13 and 16 days than mean fixed wet weights of the M. complexus. Values increase slowly during this interval (but the apparent

TABLE 1.—Mean fixed wet weights (mgs) of paired M. complexus and paired lateral cervical fat organs

Age (days of incubation)	Number of Specimens	Musculus complexus (mgs)	Standard Error	Lateral Cervical Fat Organs (mgs)	Standard Error
13	5	29.19	±2.12	35.52	±2.87
15	5	39.72	±3.93	54.42	±6.49
16	5	45.28	±3.19	64.98	±5.29
18	5	172.56	±20.35	116.80	±12.08
19	6	177.79	±14.04	131.11	±15.18
20	21	315.00	±22.49	211.58	±9.07
21 (just hatched)	21	346.20	±19.68	202.91	±8.19
22 (1 day post-hatching)	21	245.91	±11.13	196.41	±7.93
23 (2 days post-hatching; unfed)	21	192.34	±6.40	157.97	±6.45
23 (2 days post-hatching; fed)	6	187.86	±17.99	187.83	±16.99
24 (3 days post-hatching; unfed)	24	149.29	±5.97	117.24	±8.70
24 (3 days post-hatching; fed)	18	149.64	±4.75	131.52	±6.57

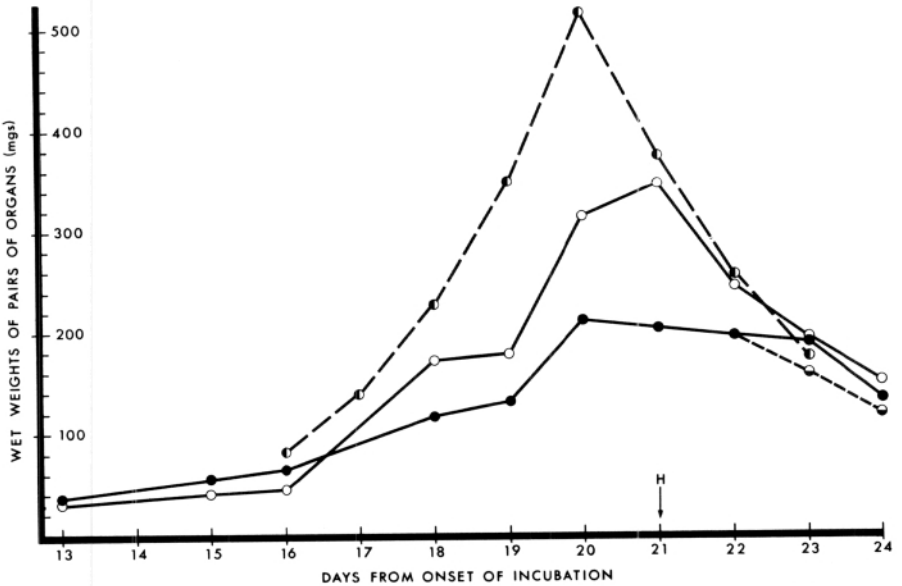

FIGURE 15. Comparison of changes in mean fresh weights of the paired M. complexus (shaded vertical half circles, unpublished data of Watterson and Veneziano from Smail, 1965) and mean fixed wet weights of the paired M. complexus (open circles) with mean fixed wet weights of pairs of lateral cervical fat organs (closed circles). At 23 and 24 days values for fat organs are plotted separately for fed (closed circles) and unfed (shaded horizontal half circles) chicks.

increase from 15 to 16 days is not statistically significant). Thereafter they increase less rapidly than those of the M. complexus to 20 days. The apparent difference between 18- and 19-day values is not statistically significant. Values remain unchanged at 21 to 23 days in fed chicks, then decrease significantly. In unfed chicks values decrease significantly at both 23 and 24 days. Mean fixed wet weights of lateral cervical fat organs in fed chicks are approximately the same as mean fixed wet weights of the M. complexus at 23 and possibly at 24 days; they are somewhat smaller than the latter in unfed chicks.

DISCUSSION

Many investigations have demonstrated that a large amount of fluid accumulates in the M. complexus of various birds just prior to pipping (Keibel, 1912; Pohlman, 1919; H. Fisher, 1958, 1961, 1962, 1966; Brandstetter, 1960; George and Iype, 1963; Smail, 1964, 1965; Watterson *et al.*, 1964; Brooks and Ungar, 1967; Bock and Hikida, 1968, 1969; Klicka *et al.*, 1969; Ramachandran *et al.*, 1969). Consequently, at the time of pipping, the muscle is very turgid and muscle bundles, as well as individual muscle fibers within bundles, are widely separated

from one another (Fisher, 1958; Brandstetter, 1960; Bock and Hikida, 1968, 1969).

According to H. Fisher (1962, 1966) and J. Fisher (1962) the fluid content of the M. complexus is somehow transferred to it from structures immediately bordering the muscle which they designated as lymph glands, lymph nodes or lymph areas. However, grebes lack such structures; nevertheless the M. complexus is selectively infiltrated with fluid just prior to pipping (Fisher, 1961). Moreover, Smail (1965) pointed out that a flow of lymph into a muscle would be surprising and Bock and Hikida (1969) noted that such a hypothetical flow of fluid would encounter considerable resistance due to the turgidity of the M. complexus. The latter investigators completely rejected the hypothesis of a flow of lymph into the hatching muscle from outside sources and reiterated their earlier suggestion (Bock and Hikida, 1968) that the lymph arises within the muscle due to osmotic pressure generated there, a possibility suggested earlier by Smail (1965). George and Iype (1963) suggested that the increased water content of the M. complexus might represent metabolic water resulting from vigorous muscular activity.

The present investigation demonstrates that the structures adjacent to the M. complexus of developing chicks are not lymph glands. Instead, on the basis of their location, size, shape and histogenesis they appear to be the lateral cervical fat organs of Liebelt and Eastlick (1954). Their histogenesis is the same as that of various normal subcutaneous fat depots described by Clara (1929) in a variety of birds. Moreover, the histogenetic changes in these structures are the same as those which occur in fat organs which develop in chick limb buds transplanted to the coelom of host embryos (Eastlick and Wortham, 1947; Miller and Eastlick, 1952). Preliminary observations indicate that the structures bordering the developing M. complexus of White Pekin ducks are also fat organs. Such findings should terminate debates about the possible transfer of fluid to the M. complexus from structures immediately bordering these muscles, at least in chick and duck embryos, and should focus attention on developmental changes within the M. complexus itself which might be responsible for the selective accumulation of fluid by this muscle.

According to H. Fisher (1962, 1966) the structures bordering the M. complexus of various birds increase and decrease in size more or less parallel to changes in size of the muscle itself. The present investigation demonstrates that mean fixed wet weights of the lateral cervical fat organs bordering the M. complexus of chick embryos tend to increase and decrease in somewhat similar fashion except at 21 days of incubation (Fig. 15), especially in unfed chicks. Similarly, the present investigation demonstrates that diameters of vacuoles in the largest univacuolar fat cells of the lateral cervical fat organs of the chick (and thus diameters of the cells themselves) increase to maximal values at 19-20 days of incubation and decrease rapidly in posthatching stages. Such findings suggest that

the fat content of the lateral cervical fat organs is broken down in part at the time of pipping and hatching, possibly to provide fatty acids as energy sources for the muscular activity involved in these processes.

In this connection it is interesting that by 19 or 20 days of incubation lipoprotein lipase, one of the enzymes capable of splitting fatty acid from parent triglycerides, exhibits a surge of activity in lateral thoracic fat organs of chick embryos (Feldman *et al.*, 1962b). Should such a surge of activity of this enzyme likewise occur at this time in other subcutaneous fat organs of chick embryos, including the lateral cervical fat organs bounding the M. complexus, the decreased diameters of the largest fat cells and the reduction in mean fixed wet weights of the lateral cervical fat organs of posthatching stages could be accounted for without assuming that these changes were related only to developmental changes undergone by the M. complexus. Even so, the latter muscle might profit more from these changes in fat organs in general than other muscles. Hsiao and Ungar (1969) demonstrated a 40% decrease in total lipid content and a 41% decrease in triglyceride content in the hatching muscle between 17 and 21 days of incubation, compared with decreases of only 25% and 11%, respectively, in shank (gastrocnemius) muscles. This suggests, contrary to George and Iype (1963) that the M. complexus may derive part of its energy from fat as well as from its glycogen content. The latter is depleted or sharply decreased by 21 days of incubation (see also Klicka *et al.*, 1969, and Ramachandran *et al.*, 1969) although the acid mucopolysaccharide content increases markedly at 20 days of incubation (Klicka *et al.*, 1969). More complete utilization of its own total lipid and triglyceride stores might make the M. complexus more dependent on fatty acids released into the blood from fat organs than other skeletal muscles, at least during pipping and hatching (see Feldman *et al.*, 1962a).

Summary

The gross relationships and histogenesis of the structures immediately lateral to the Musculus complexus of chick embryos have been described. These structures are typical fat organs and not lymph glands, as they have been designated by some investigators. Their mean fixed wet weights increase and decrease somewhat parallel with changes in mean fixed wet weights of the M. complexus, as do the diameters of the fat vacuoles of the largest univacuolar fat cells. These findings suggest that the fat content of subcutaneous fat organs is broken down in part at the time of pipping and hatching, possibly to provide fatty acids as energy sources for the muscular activity involved in these processes. It is suggested that fatty acids released into the blood from fat organs might be more important energy sources for the M. complexus than for other skeletal muscles at this time.

Literature Cited

Beddard, F. E. 1898. The Structure and Classification of Birds. Longmans, and Co., London.

BOCK, W. J., and R. S. HIKIDA. 1968. An analysis of twitch and tonus fibers in the hatching muscle. Condor, *70*: 211-222.

————, and R. S. HIKIDA. 1969. Turgidity and function of the hatching muscle. Amer. Midl. Natur., *81*: 99-106.

BRANDSTETTER, W. E. 1960. Development of the "hatching muscle" (*Musculus complexus*) in unoperated, hypophysectomized and thiourea-treated chick embryos. Ph. D. Dissertation, Northwestern University.

BROOKS, W. S., and F. UNGAR. 1967. Effect of C_{21}-methyl steroids on the *Musculus complexus* and hatching of the chick. Proc. Soc. Exp. Biol. Med., *125*: 489-492.

CLARA, M. 1929. Bau und Entwicklung des sogenannten Fettgewebes beim Vogel. Z. mikrosk.-anat. Forsch., *19*: 32-113.

EASTLICK, H. L., and R. A. WORTHAM. 1947. Studies on transplanted embryonic limbs of the chick. III. The replacement of muscle by "adipose tissue." J. Morphol., *80*: 369-389.

FELDMAN, G. L., L. M. CHURCHWELL, T. W. CULP, F. A. DOYLE and H. T. JONSSON. 1962a. The lipid content of the subcutaneous fat organs of the chick embryo. Poult. Sci., *41*: 1232-1240.

————, F. A. DOYLE, M. R. LAWLER, JR., R. S. RODGERS and L. M. CHURCHWELL. 1962b. Enzymatic activity of the developing subcutaneous fat organs of the chick. Poult. Sci., *41*: 1423-1428.

FISHER, H. I. 1958. The "hatching muscle" in the chick. Auk, *75*: 391-399.

————. 1961. The hatching muscle in North American grebes. Condor, *63*: 227-233.

————. 1962. The hatching muscle in Franklin's gull. Wilson Bull., *74*: 166-172.

————. 1966. Hatching and the hatching muscle in some North American ducks. Trans. Illinois State Acad. Sci., *59*: 305-325.

FISHER, J. R. 1962. The hatching muscle in the American coot. Trans. Illinois State Acad. Sci., *55*: 71-77.

GEORGE, J. C., and A. J. BERGER. 1966. Avian Myology. Academic Press, New York.

————, and P. T. IYPE. 1963. The mechanism of hatching in the chick. Pavo, *1*: 52-56.

HAMILTON, H. L. 1952. Lillie's Development of the Chick. Holt, Rinehart and Winston, New York.

HSIAO, C. Y. Y., and F. UNGAR. 1969. Lipid changes in the chick hatching muscle. Proc. Soc. Exp. Biol. Med., *132*: 1047-1051.

KAUPP, B. F. 1918. The Anatomy of the Domestic Fowl. W. B. Saunders Co., Philadelphia.

KEIBEL, F. 1912. Wie zerbricht der ausschlüpfende Vogel die Eischale? Anat. Anz., *41*: 381-382.

KLICKA, J., R. EDSTROM and F. UNGAR. 1969. Acid mucopolysaccharide changes in chick hatching muscle. J. Exp. Zool., *171*: 249-251.

LIEBELT, R. A., and H. L. EASTLICK. 1954. The organ-like nature of the subcutaneous fat bodies in the chicken. Poult. Sci., *33*: 169-179.

MILLER, J. E., and H. L. EASTLICK. 1952. Studies on transplanted embryonic limbs of the chick. IV. The cytology of the "adipose tissue." Trans. Amer. Microscop. Soc., *71*: 1-19.

POHLMAN, A. G. 1919. Concerning the causal factor in the hatching of the chick, with particular reference to the Musculus complexus. Anat. Rec., *17*: 89-104.

RAMACHANDRAN, S., J. KLICKA and F. UNGAR. 1969. Biochemical changes in the musculus complexus of the chick (*Gallus domesticus*). Comp. Biochem. Physiol., *30*: 631-640.

SMAIL, J. R. 1964. A possible role of the Musculus complexus in pipping the chicken egg. Amer. Midl. Natur., *72*: 499-506.

SMAIL, J. R. 1965. Biochemical changes in the Musculus complexus of chick embryos with emphasis on problems associated with hatching. Ph. D. Dissertation, University of Illinois, Urbana.

WATTERSON, R. L., A. J. BART and W. E. BRANDSTETTER. 1964. Some quantitative changes in projected cross-sectional areas of muscle fibers and interfiber areas in the hatching muscle (musculus complexus) of White Leghorn chicks in late incubation and early posthatching stages. Anat. Rec., *148*: 348.

Manuscript received August 31, 1970.

LEGENDS

PLATE I

FIGURE 1. Boundaries of the right lateral cervical fat organ in a newly hatched (21-day) chick are indicated by white arrows; MC = M. complexus. X2

FIGURE 2. Transverse section through the neck of a 15-day (stage 41) chick embryo at the level of the second vertebra. FO = lateral cervical fat organ; E = esophagus. X15

FIGURE 3. Parasagittal section through the upper neck and posterior head of a 12-day (stage 38) chick embryo. Arrows indicate boundaries of the lateral cervical fat organ. HA = hyoid arch; T = thymus gland. X16.

FIGURE 4. Transverse section through the rudiment of one lateral cervical fat organ before fat deposition begins (11 days, stage 37). X198.

PLATE II

FIGURE 5. Part of the lateral cervical fat organ at 12 days (stage 38). Magnification of Figures 5-14 x160.

FIGURE 6. Part of the lateral cervical fat organ at 13 days (stage 39). CT = connective tissue septum.

FIGURE 7. Part of the lateral cervical fat organ at 15 days (stage 41).

FIGURE 8. Part of the lateral cervical fat organ at 16 days (stage 42). Arrows indicate irregularly shaped plurivacuolar fat cells.

FIGURE 9. Part of the lateral cervical fat organ at 19-20 days (stage 45).

FIGURE 10. Part of the lateral cervical fat organ 1 day posthatching.

PLATE III

FIGURE 11. Part of the lateral cervical fat organ 3 days posthatching (unfed chick).

FIGURE 12. Part of the lateral cervical fat organ 6 days posthatching (fed).

FIGURE 13. Part of the lateral *abdominal* fat organ in a newly hatched (21-day) chick.

FIGURE 14. Part of the lateral *thoracic* fat organ in a newly hatched (21-day) chick.